

# Intrastromal corneal ring segment implantation with the femtosecond laser in a post-keratoplasty patient with recurrent keratoconus

Efekan Coskunseven, MD, George D. Kymionis, MD, PhD, Haluk Talu, MD, Ebru Aslan, Vasilios F. Diakonis, MD, Dimitrios I. Bouzoukis, MD, Ioannis Pallikaris, MD, PhD

A 50-year-old woman had implantation of intrastromal corneal ring segments for recurrent keratoconus 15 years after penetrating keratoplasty. Two segments (0.15 mm and 0.25 mm) were inserted without any intraoperative or postoperative complications, using the femtosecond laser to create the tunnels (superior and inferior). Ten months after the procedure, the uncorrected visual acuity was 20/100, compared with counting fingers preoperatively, and the best spectacle-corrected visual acuity improved from 20/63 to 20/32. Although the results are encouraging, the long-term effect of this approach for the management of post-keratoplasty patients with recurrent keratoconus is not known.

*J Cataract Refract Surg* 2007; 33:1808–1810 © 2007 ASCRS and ESCRS

Penetrating keratoplasty (PKP) is a safe and effective procedure for patients with keratoconus. However, recurrent keratoconus remains a post-PKP problem, even for expert surgeons, and cannot always be corrected by spectacles or contact lenses.

In addition to the incisional surgical options described in the literature, excimer laser surgery (eg, photorefractive keratectomy and laser in situ keratomileusis [LASIK]) is used increasingly to correct post-PKP astigmatism due to reports of its safety and efficacy.<sup>1–3</sup> Despite the encouraging results, especially after LASIK in post-PKP corneas, several limitations (such as patients with thin corneas) should be considered to avoid post-refractive surgery complications similar to those in refractive patients.

Intrastromal corneal ring segments (ICRS) were first used in patients with low myopia, but several studies demonstrate the efficacy of intrastromal rings in

keratoconic eyes.<sup>4,5</sup> To avoid the complications and unsuitability of refractive surgery in patients with thin corneal grafts and recurrent keratoconus after PKP, ICRS implantation could be used because of the tissue-saving characteristics of the technique.

We describe ICRS implantation in a post-PKP patient with a thin cornea and keratoconus recurrence (unsuitable for laser refractive surgery and contact lens intolerant).

## CASE REPORT

A 50-year-old woman was referred for refractive surgery correction in the right eye 15 years after PKP for keratoconus. The preoperative uncorrected visual acuity (UCVA) was counting fingers at 1 meter, and the best spectacle-corrected visual acuity (BSCVA) was 20/63 with  $-3.50 -5.50 \times 90$ .

Biomicroscopy showed a clear corneal graft that was slightly decentered temporally. Fundoscopy was normal. The central corneal ultrasound pachymetry (Sonogage 50 Hz) was 470  $\mu\text{m}$ , and the keratometry was 50.9@7/45.1@97. Corneal topography showed irregular astigmatism (Figure 1).

The patient was scheduled for ICRS implantation (Keraring Mediphacos Ophthalmic Professionals). She was informed of the possible intraoperative and postoperative complications and gave written informed consent in accordance with institutional guidelines and the Declaration of Helsinki.

## Surgical Procedure

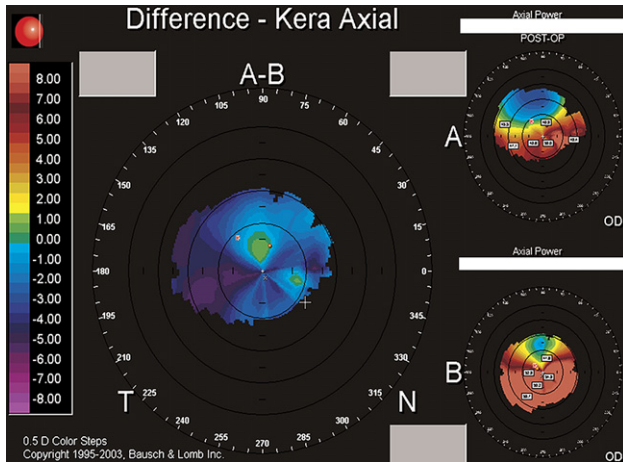
The surgical procedure was performed under topical anesthesia. The Wavelight laser's microscope (WaveLight Laser Technologie AG) was used to mark the Purkinje

Accepted for publication May 21, 2007.

From the World Eye Hospital (Coskunseven, Talu, Aslan), Istanbul, Turkey; and the Institute of Vision and Optics (Kymionis, Diakonis, Bouzoukis, Pallikaris), University of Crete, Greece.

No author has a financial or proprietary interest in any material or method mentioned.

Corresponding author: George D. Kymionis, MD, PhD, Bascom Palmer Eye Institute, Miller School of Medicine, University of Miami, Florida, USA. E-mail: [kymionis@med.uoc.gr](mailto:kymionis@med.uoc.gr).



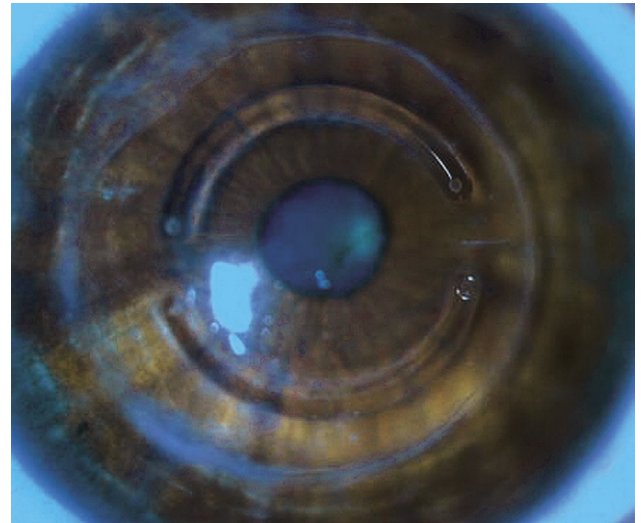
**Figure 1.** Topography of the eye with post-PKP irregular astigmatism before (*bottom right*) and 10 months after (*top right*) ICRS implantation.

reflection as the central point of the ICRS implantation. Centration was essential because the keratoplasty graft was slightly decentered temporally (diameter of the graft was 8.0 mm). The implantation was centered slightly eccentrically and nasally to compensate for the temporal graft decentration. To avoid placing the tunnels at the graft-host intersection, creation of the tunnels was done very carefully. Peripheral corneal thickness along the tunnel location in the cornea was measured intraoperatively with ultrasonic pachymetry. Of approximately 10 measurements at this location, the thinnest value was 470  $\mu\text{m}$ . The incision depth was taken as 80% of 470  $\mu\text{m}$ . The incision site was chosen at the topographic steepest axis. The preoperative manifest refraction was  $-3.50 -5.50 \times 90$ . Segment thickness was chosen according to the Keraring nomogram, taking the ectatic area and preoperative spherical equivalent refraction into consideration.

The tunnels were created using the IntraLase FS 60 femtosecond laser. The central point was the marked Purkinje reflection. The incision site was 7 degrees and the depth, 376  $\mu\text{m}$ . The IntraLase settings were inner diameter 4.4 mm, outer diameter 5.6 mm, entry cut thickness 1  $\mu\text{m}$ , ring energy 1.30, and entry cut energy 1.30. Creation of the tunnels took 8 seconds.

After the original insertion was reopened with a Gruper-macher delaminator, the ICRS were implanted with Albertazzi forceps on the flat axis at symmetrical positions. The tips were far from the incision site. The segment was implanted with flat side down. Two segments of 150  $\mu\text{m}$  and 250  $\mu\text{m}$  were implanted in the superior tunnel and inferior tunnel, respectively (at a 5.0 mm diameter). Placing sutures at the incision site was avoided because the cornea was very thin at this location (at the 5.0 mm diameter), increasing the risk for corneal perforation, and the stromal tunnel and incision creation using the femtosecond laser were very accurate, minimizing the risk for segment extrusion.

No intraoperative or postoperative complications were seen (*Figure 2*). A therapeutic soft contact lens was used until the incision was completely healed (the first postoperative



**Figure 2.** Slitlamp photograph of a post-PKP eye after ICRS implantation in a 5.0 mm diameter implantation zone.

day). One month postoperatively, the UCVA was 20/100 and the BSCVA, 20/32; the manifest refraction was  $+0.25 -3.25 \times 110$ .

Ten months postoperatively, the UCVA in the right eye was 20/100; the BSCVA was 20/32 and the manifest refraction,  $+0.50 -3.50 \times 105$ . Corneal topography revealed a topographic flattening effect after ICRS implantation (*Figure 1*).

## DISCUSSION

Post-PKP residual refractive error and astigmatism are frequent findings, and their management continues to be a challenging problem. Despite the encouraging results of excimer laser refractive surgery (especially LASIK), the techniques are not suitable for every patient since there are several contraindications and exclusion criteria; ie, patients with thin corneas, abnormal topographic patterns, dry eye, and high ametropia.

Preoperative central corneal thickness (CCT) is one of the most important eye measurements to determine whether a patient is a good candidate for refractive surgery. Preoperative CCT greater than 500  $\mu\text{m}$  and a residual corneal bed thickness greater than 250  $\mu\text{m}$  (or 300  $\mu\text{m}$ ) are considered cut-off values by most surgeons.<sup>6,7</sup> Furthermore, these limitations are crucial and should always be taken into consideration in post-PKP cases, in which meridian and corneal stresses are caused by irregularities in wound shape and healing.


In our post-PKP patient, ICRS implantation was performed for a residual refractive error and keratoconus recurrence. The patient had irregular astigmatism and a thin cornea, which made her unsuitable for laser refractive surgery correction. Ten months after the

procedure, the UCVA was 20/100, compared with counting fingers preoperatively, and the BSCVA improved to 20/32 from 20/63 due to improvement in topographic findings and astigmatism.

In conclusion, ICRS implantation may be an alternative, minimally invasive treatment for residual refractive surgery correction in post-PKP patients with keratoconus recurrence who are unsuitable for LASIK, despite the limitation of this report including only 1 patient. In post-graft cases, especially those with decentered grafts, implanting segments in a 5.0 mm diameter zone seems to be very promising since this avoids a ring passing along the graft-host junction. Further studies are needed to draw conclusions about the efficacy and safety of this technique in post-PKP patients.

## REFERENCES

1. Mann E, Zaidman GW, Shukla S. Efficacy of nonsimultaneous bilateral LASIK after nonsimultaneous bilateral penetrating keratoplasty. *Cornea* 2006; 25:1053–1056
2. Buzard K, Febraro I-L, Fundingsland BR. Laser in situ keratomileusis for the correction of residual ametropia after penetrating keratoplasty. *J Cataract Refract Surg* 2004; 30:1006–1013
3. Kymionis GD, Tsiklis NS, Astyrakakis N, et al. Eleven-year follow-up of laser in situ keratomileusis. *J Cataract Refract Surg* 2007; 33:191–196
4. Kymionis GD, Tsiklis NS, Pallikaris AI, et al. Long-term follow-up of Intacs for post-LASIK corneal ectasia. *Ophthalmology* 2006; 113:1909–1917
5. Kymionis GD, Siganos CS, Kounis G, et al. Management of post-LASIK corneal ectasia with Intacs inserts; one-year results. *Arch Ophthalmol* 2003; 121:322–326
6. Pallikaris IG, Kymionis GD, Astyrakakis NI. Corneal ectasia induced by laser in situ keratomileusis. *J Cataract Refract Surg* 2001; 27:1796–1802
7. Kohnen T. Iatrogenic keratectasia: current knowledge, current measurements [editorial]. *J Cataract Refract Surg* 2002; 28:2065–2066



First author:

Efeke Coskunseven, MD

*World Eye Hospital, Istanbul, Turkey*