

Complications of intrastromal corneal ring segment implantation using a femtosecond laser for channel creation: a survey of 850 eyes with keratoconus

Efekan Coskunseven,¹ George D. Kymionis,² Nikolaos S. Tsiklis,² Serife Atun,¹ Ebru Arslan,¹ Charalambos S. Siganos,² Mirco Jankov³ and Ioannis G. Pallikaris²

¹Dunya Eye Hospital, Istanbul, Turkey

²Institute of Vision and Optics, University of Crete, Greece

³Milos Klinika, Medical Academy-US Medical School, Belgrade, Serbia

ABSTRACT.

Purpose: To report complications after the implantation of intrastromal corneal ring segments (Keraring; Mediphacos, Belo Horizonte, Brazil) in keratoconic eyes using a femtosecond laser (IntraLase; Advanced Medical Optics, Santa Ana, California, USA) for channel creation.

Methods: Retrospective chart review of 531 patients (850 eyes) who underwent Keraring insertion using a femtosecond laser for channel creation. Intraoperative and postoperative complications were recorded.

Results: Intraoperatively, there were 22 (2.7%) cases of incomplete channel formation. The rest of the intraoperative complications were galvo lag error (system malfunction) [five eyes (0.6%)], endothelial perforation [five eyes (0.6%)] and incorrect entry of the channel [two eyes (0.2%)]. Postoperatively, there were 11 (1.3%) cases of segment migration, two (0.2%) cases of corneal melting and one (0.1%) case of mild infection. The overall complication rate was 5.7% (49 cases out of 850 eyes).

Conclusion: In this study, intracorneal ring segment implantation using a femtosecond laser for channel creation was related to a number of complications. The most common complications were incomplete channel creation (intraoperatively) and segment migration (postoperatively).

Key words: femtosecond laser – intrastromal corneal ring segments – keratoconus

Acta Ophthalmol. 2011; 89: 54–57

© 2009 The Authors

Journal compilation © 2009 Acta Ophthalmol

doi: 10.1111/j.1755-3768.2009.01605.x

Introduction

The implantation of intracorneal ring segments is a minimally invasive surgical procedure for keratoconic (Kymionis et al. 2007) or post-LASIK (Laser *in Situ* Keratomileusis) ectatic (Kymionis et al. 2006) corneas. Before the introduction of femtosecond laser technology, channel creation was accomplished manually using mechanical devices (Ruckhofer et al. 2001; Kanellopoulos et al. 2006; Zare et al. 2007). This step of the procedure was related with a number of possible complications such as epithelial defects, anterior or posterior corneal perforations, infectious keratitis, asymmetric segment placement, corneal stromal oedema around the incision, extension of the incision towards the central visual axis or the limbus and persistent incisional gapping (Ruckhofer et al. 2001; Kanellopoulos et al. 2006; Zare et al. 2007). Recently, channel creation has been performed using the femtosecond laser, which can deliver energy accurately to a precise depth in a

programmed way. Studies indicate that Intacs implantation using a femtosecond laser is a safe and effective procedure for treating keratoconic corneas (Ratkay-Traub et al. 2003; Carrasquillo et al. 2007; Ertan et al. 2006; Ertan & Bahadir 2007; Ertan et al. 2007; Coskunseven et al. 2008; Sugar 2002; Shabayek & Alió 2007). The femtosecond laser minimizes procedure time and decreases the risk of inflammation or infection.

There are several different types of intracorneal rings, with varying curvature, width and zone of implantation. The Keraring (Mediphacos, Belo Horizonte, Brazil) is a newly developed implantable intrastromal corneal ring segment made of polymethyl methacrylate (PMMA) and is characterized by a triangular cross-section that induces a prismatic effect on the cornea. The Keraring's apical diameter is 5 mm and the flat basis width is 0.6 mm, with variable thickness (0.15–0.30 mm thickness with 0.5 mm steps) and arc lengths (90, 160 and 210 degrees).

To our knowledge, this study is the first large clinical trial examining the complications of this type of intracorneal ring segment using the femtosecond laser for channel creation in keratoconic patients.

Materials and Methods

Eight hundred and fifty eyes (531 patients) with mild to moderate keratoconus underwent intrastromal corneal ring segment implantation (Keraring) using a Femtosecond laser (IntraLase; Advanced Medical Optics, Santa Ana, California, USA) for channel creation. All patients gave informed consent prior to their operation, in adherence to institutional guidelines and the tenets of the Declaration of Helsinki.

A complete ophthalmological examination was performed preoperatively, including uncorrected visual acuity (UCVA), best spectacle-corrected visual acuity (BSCVA), manifest refraction, biomicroscopy, corneal topography [Orbscan IIz (Bausch & Lomb, Rochester, New York, USA), WaveLight Allegretto Topolyzer (WaveLight Laser Technologie, Erlangen, Germany)] and endothelial cell density measurement with specular microscopy (Konan Specular Microscope SP 9000 Noncon Robo Pachy; Konan Medical Inc., Hyogo, Japan).

All patients had clear central corneas without scars and were contact lens intolerant. Corneal thickness was at least 350 μm at the tunnel location. Patients were excluded if any of the following criteria applied after the preoperative examination: history of herpes, keratitis, corneal dystrophies, diagnosed autoimmune disease, systemic connective tissue disease, acute or grade IV keratoconus, and endothelial cell count of < 1000 cells/ mm^2 .

All procedures were performed under sterile conditions and with topical anaesthetic drops. The Purkinje reflex was chosen as the central point and marked under the WaveLight Allegretto biomicroscope. A 5-mm marker was used to locate the exact ring channel. Corneal thickness was measured intraoperatively using ultrasonic pachymetry (Sonogage, Cleveland, Ohio, USA) along the ring location markings. Tunnel depth was set at 80% of the thinnest corneal thickness on the tunnel location. Arc length and thickness were chosen according to the manufacturer's nomogram. A 60 kHz femtosecond laser was used to create the ring channels. The channel's inner diameter was set to 4.4 mm, and the outer diameter was 5.6 mm. The entry cut thickness was 1 μm , and the ring energy used for channel creation was 1.30 μJ . The entry cut energy was 1.30 μJ and channel creation timing with the femtosecond laser was 15 seconds. The intracorneal ring segments were implanted immediately after channel creation, before the bubbles

disappeared, as they revealed the exact tunnel location. To avoid any injury to the incision area, the segment was implanted directly using the special Keraring forceps.

Mean patient age was 28.32 ± 7.28 years (range 18–44 years). Intraoperative and postoperative complications were recorded.

Results

The overall complication rate was 5.7% (49 cases).

Intraoperative complications

Incomplete channel formation occurred in 22 eyes (2.6%). In these eyes, channels were completed using a mechanical separator (Fig. 1).

Galvanometer lag error (system malfunction) occurred in five cases (0.6%). In all cases the error occurred 2 seconds before the completion of the incision. In two of the cases, the procedure was restarted and the error occurred again at exactly the same time. A 30-degree knife was then used to complete the incision.

There were five (0.6%) cases of endothelial perforation, which were present intraoperatively as bubbles in the anterior chamber. In the first two patients, the ring was displaced initially, moving into the anterior chamber. In the third and fourth cases, we recognized endothelial perforation during the channel creation. The channel was recreated with a targeted depth of 30 μm superficially compared




Fig. 1. Incomplete channel formation: bridges around the segment. In these eyes, channels were completed using a mechanical separator.

with the original channel at the same time with the same vacuum. Oedema was prevalent around the segment in these cases. In the last case the procedure was postponed for 1 month. Channel was recreated 90 μm superficially to protect the endothelium. Incorrect entry of the channel occurred in two eyes (0.2%) while using the 150 μm ring. A second channel was created using a mechanical separator.

Vacuum loss occurred in one eye (0.1%). Vacuum was created again at the same conjunctival and corneal plan and the same corneal marking was used. The channel was completed successfully at the same location and depth. The overall intraoperative complication rate was 4.1% (35 cases).

Postoperative complications

Segment displacement was observed in 11 cases (0.8%). In seven cases the segments migrated in the channel; a suture was placed at the incision and removed 2 months later, preventing any further migration. In four eyes there was a superficial movement of the segments (Fig. 2). All of the segments were removed before corneal melting occurred.

Corneal melting was observed in two eyes (0.2%). In both cases corneal melting was noted above the segments because of the superficial placement of the rings; we performed a segment explantation with no further incidences.

There was one (0.1%) case of infection following implantation. The patient experienced corneal abscess formation at the incision site, which was treated with intense antibiotics. The overall postoperative complication rate was 1.6% (14 cases).

Discussion

The first study ever published about segment implantation (Intacs) with the use of femtosecond laser (Ratkay-Traub et al. 2003) reported no intraoperative complications and minimal deposits in the channels of two eyes (12.5%). Carrasquillo et al. (2007) also reported no intraoperative complication during the use of femtosecond laser for channel creation. Postoperatively, two eyes (12.5%) developed corneal neovascularization and one eye (6.25%) had a fungal

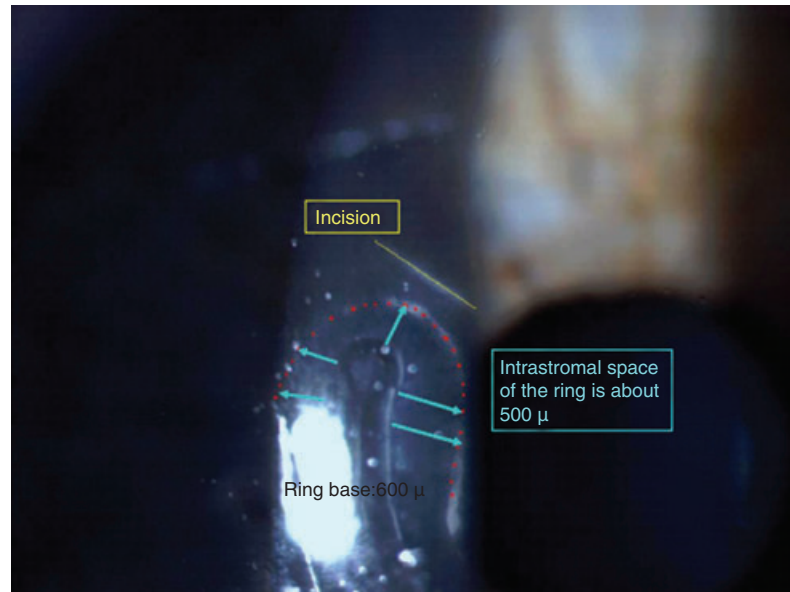


Fig. 2. Segment develops empty space around itself. This is the first step before the superficial movement of the ring.

infection 7 months after surgery. In three studies of segment implantation with the use of femtosecond laser, Ertan et al. found that epithelial plugs were the most common complication, occurring in 15.2% (Ertan et al. 2006) and 24.6% (Ertan et al. 2007) of eyes; meanwhile, segment migration occurred in three eyes (4.5%) (Ertan & Bahadır 2007).

In the only comparative study regarding Intacs inserts using the femtosecond laser or a mechanical spreader, Rabinowitz et al. (2006) reported that three patients (15%) had significant epithelial defects and one patient (5%) had a gram-positive infection during the postoperative period in the femtosecond group. In the mechanical spreader group, one patient (5%) had Intacs extraction caused by superficial placement of the segment.

In other studies examining segment implantation using the traditional mechanical method, Kanellopoulos et al. (2006) reported six (30%) cases of intracorneal ring segment movement and one (5%) case of corneal melt. Ruckhofer et al. (2001) reported corneal perforation to be the most common complication [four eyes (2.4%)], while Zare et al. (2007) reported segment movement and exposure to be the most common [three eyes (10%)].

There are two studies regarding Kerarings implantation using femtosecond laser for channel creation.

Coskunseven et al. (2008) reported no intraoperative complications and three (6%) cases of segment migration in 50 eyes, while Shabayek & Alió (2007) reported one eye with infectious keratitis (4.8%) and eight eyes (38%) with incision opacification. In the current study, we found 33 (4%) and 14 (1.6%) complicated cases during or immediately after the procedure, respectively. The discrepancy between the complication rates reported in the literature is mainly the result of variations in the number of eyes studied (we included 850 eyes in the current study) and differences in segment characteristics (Intacs or Kerarings).

Incomplete channel creation and segment migration were the most common intraoperative and postoperative complications, respectively. Incomplete channel formation occurred in 22 (2.6%) eyes, and all the procedures were completed with the use of a mechanical spreader. This is probably caused by the insufficient energy levels of the laser. This complication can be minimized by increasing the energy levels or by decreasing spot separation. Segment displacement was observed in 11 cases (0.8%). In seven cases the segments migrated in the channel and a corneal suture was placed at the incision site to prevent any further migration. In the other four eyes, segments were moved superficially and explanted before corneal melting occurred.

Galvanometer lag error, a technical problem of the device, was noticed in five eyes (0.6%). The error is located at the memory system of the femtosecond, which is unable to recall the operation centre if that centre has changed. In such an event, a second channel has to be created next to the previous one. Additionally, the system does not have a separate incision cut program, therefore when the procedure is restarted it begins with channel creation. To avoid the galvo error during channel creation, it is important to maintain the vacuum. If the galvo error does occur, the surgery should be postponed and the second surgery should be performed using the same cone (using a depth of 30 μm superficially). If the galvo error is experienced during incision creation, the incision should be continued with a blade, even if there is only 1 second remaining. Using the blade, another channel can be created above or below the original plane immediately before the bubbles disappear, so that it is easier to locate the channel.

Endothelial perforation occurred in five eyes in our study (0.6%). It can be caused by incorrect preoperative pachymetry or deeper channel creation. Femtosecond channel creation is very predictable but each cone has a 10–15 μm standard deviation. To avoid the incidence of endothelial perforation, it is important to achieve correct and accurate pachymetry in a 5-mm optical zone at the implantation site. The reference point should be the point of thinnest pachymetry at the channel locations. Endothelial perforation can be prevented by stopping channel creation as soon as the complication is recognized before the incision. Femtosecond channel creation is circular, rather than raster, starting from the central and continuing into the periphery. If bubbles are noted, and endothelial perforation appears to be the case, surgery should be postponed for at least 1 month. Then a new channel should be created 90 μm superficially to protect the endothelium (Kanellopoulos et al. 2006).

Incorrect entry of the channel occurred in two eyes (0.2%). This complication may have been caused because a channel starter was not used. If a surgeon delays, the bubbles in the channel disappear. Therefore, during the positioning of the segments

a second channel in another corneal depth can be formed.

Postoperatively, corneal melting was noted in two eyes. Patients with superficial placement of the ring, with very thin corneas or who have undergone incorrect corneal pachymetry represent the highest risk. In the event of corneal melting, the ring has to be explanted immediately.

Vacuum loss occurred in one (0.1%) eye during channel creation. If vacuum loss occurs during incision it is possible to create the vacuum again at the same conjunctival and corneal plain, following the same marks to create the channel at the same location and depth. If we preferred to continue with a diamond knife, the bubbles in the channel would be the reference point that would help us to locate the channel more easily.

The most severe and potentially sight-threatening complications were endothelial perforation (intraoperatively), corneal melting and infection (postoperatively) [eight cases (0.9%)].

This article has several potential limitations: the retrospective nature of the study, the absence of a comparative mechanical group and the visual/refractive outcomes of the participants.

In conclusion, we describe several complications of intrastromal corneal ring segment (Kerarrings) implantation with femtosecond laser for channel creation. The most common complications were incomplete channel creation (intraoperatively) and segment migration (postoperatively).

References

- Carrasquillo K, Rand J & Talamo JH (2007): Intacs for keratoconus and post-LASIK ectasia. Mechanical versus femtosecond laser-assisted channel creation. *Cornea* **26**: 956–962.
- Coskunseven E, Kymionis GD, Tsiklis NS, Atun S, Arslan E, Jankov MR & Pallikaris IG (2008): One-year results of intrastromal corneal ring segment implantation (Keraring) using femtosecond laser in patients with keratoconus. *Am J Ophthalmol* **145**: 775–779.
- Ertan A & Bahadır M (2007): Topography-guided vertical implantation of Intacs using a femtosecond laser for the treatment of keratoconus. *J Cataract Refract Surg* **33**: 148–151.
- Ertan A, Kamburoğlu G & Bahadır M (2006): Intacs insertion with the femtosecond laser for the management of keratoc-

onus. One-year results. *J Cataract Refract Surg* **32**: 2039–2042.

- Ertan A, Kamburoğlu G & Umit A (2007): Comparison of outcomes of 2 channel sizes for intrastromal ring segment implantation with a femtosecond laser in eyes with keratoconus. *J Cataract Refract Surg* **33**: 648–653.
- Kanellopoulos AJ, Pe LH, Perry HD & Donnenfeld ED (2006): Modified intracorneal ring segment implantations (INTACS) for the management of moderate to advanced keratoconus: efficacy and complications. *Cornea* **25**: 29–33.
- Kymionis GD, Tsiklis NS, Pallikaris AI, Kounis G, Diakonis VF, Astyrakakis N & Siganos CS (2006): Long-term follow-up of Intacs for post-LASIK corneal ectasia. *Ophthalmology* **113**: 1909–1917.
- Kymionis GD, Siganos CS, Tsiklis NS, Anastasakis A, Yoo SH, Pallikaris AI, Astyrakakis N & Pallikaris IG (2007): Long-term follow-up of intacs in keratoconus. *Am J Ophthalmol* **143**: 236–244.
- Rabinowitz YS, Li X, Ignacio TS & Maguen E (2006): INTACS inserts using the femtosecond laser compared to the mechanical spreader in the treatment of keratoconus. *J Refract Surg* **22**: 764–771.
- Ratkay-Traub I, Ferincz IE, Juhasz T, Kurtz RM & Krueger RR (2003): First clinical results with the femtosecond neodymium-glass laser in refractive surgery. *J Refract Surg* **19**: 94–103.
- Ruckhofer J, Stoiber J, Alzner E, Grabner G & the Multicenter European Corneal Correction Assessment Study Group (2001): One year results of European Multicenter Study of intrastromal corneal ring segments. Part 2: complications, visual symptoms, and patient satisfaction. *J Cataract Refract Surg* **27**: 287–296.
- Shabayek MH & Alió JL (2007): Intrastromal corneal ring segment implantation by femtosecond laser for keratoconus correction. *Ophthalmology* **114**: 1643–1652.
- Sugar A (2002): Ultrafast (femtosecond) laser refractive surgery. *Curr Opin Ophthalmol* **13**: 246–249.
- Zare MA, Hashemi H & Salari MR (2007): Intracorneal ring segment implantation for the management of keratoconus: safety and efficacy. *J Cataract Refract Surg* **33**: 1886–1891.

Received on November 10th, 2008.

Accepted on February 24th, 2009.

Correspondence:

Nikolaos S. Tsiklis
Institute of Vision and Optics
Department of Ophthalmology
University Of Crete
Medical School
71003 Heraklion
Crete
Greece
Tel: + 30 2810 327316
Fax: + 30 2810 394653
Email: ntsiklis@hotmail.com