Intrastromal Corneal Ring Segment Implantation for the Treatment of Keratoconus

Anıl Kubaloglu, MD, Esin Sogutlu Sari, MD, Yasin Cinar, MD, Arif Koytak, MD, Ekrem Kurnaz, MD, and Yusuf Özertürk, MD

Purpose: To evaluate the safety and efficacy of intrastromal corneal ring segment implantation using both mechanical and femtosecond-assisted tunnel creation for the treatment of patients with keratoconus.

Methods: A retrospective noncomparative interventional study including 96 eyes of 75 patients with keratoconus. All patients had contact lens intolerance and clear central corneas. Corneal tunnels were made using a femtosecond laser in 26 eyes (femtosecond group) and mechanically in 70 eyes (mechanical group). The Keraring (Mediphacos, Belo Horizonte, Brazil) was implanted in each eye, and a complete ophthalmic examination was performed, including visual acuity, refraction, and keratometric readings.

Results: The mean preoperative uncorrected visual acuity for all eyes was 1.40 ± 0.39 logarithm of the minimal angle of resolution (logMAR) (mean ± SD) and improved to 0.60 ± 0.34 logMAR at the sixth month (n = 96, $P < 0.001$) and 0.50 ± 0.32 (n = 54, $P < 0.001$) at the 18th month. The mean preoperative best spectacle–corrected visual acuity (BSCVA) for all eyes (n = 96) was 0.68 ± 0.36 logMAR. The mean BSCVA was 0.29 ± 0.21 (n = 96, $P < 0.001$) at the sixth month and improved to 0.26 ± 0.20 (n = 54, $P < 0.001$) at the 18th month. There was a significant reduction in spherical equivalent refractive error from −5.88 ± 3.65 diopters (D) (n = 96) to −2.26 ± 1.98 D (n = 54, $P < 0.001$) at the 18th month. The mean preoperative maximum keratometry (Kmax) was 53.58 ± 5.90 D and decreased to 49.02 ± 4.70 (n = 96, $P < 0.001$) at 6 months and 48.57 ± 4.36 D (n = 54, $P < 0.001$) at the 18th month. Sixth month results of the mechanical versus femtosecond groups were as follows: improvement in uncorrected visual acuity (2.08 vs. 1.50 lines), improvement in BSCVA (2.93 vs. 2.19), reduction in spherical equivalent (3.78 vs. 3.75 D), and reduction in maximum keratometry (4.66 vs. 4.62 D). There was no statistically significant difference between both groups for any parameter.

Conclusions: Keraring implantation is effective for the treatment of keratoconus, providing safety and good visual outcomes after both mechanical and femtosecond-assisted tunnel creation.

Received for publication April 30, 2009; revision received February 7, 2010; accepted February 21, 2010.

From the Dr. Lütfi Kırdar Kartal Training and Research Hospital, 2nd Eye Clinic, Istanbul, Turkey.

None of the authors have financial interests in any of the products or methods mentioned herein.

Reprints: Esin Sogutlu Sari, Altıyol Kırtasiye Sok. No 36, E–5 Yanyol Denizer Caddesi, Merkez/Kadiköy, Istanbul 34000, Turkey (e-mail: dresinsogutlu@hotmail.com).

Key Words: intrastromal corneal ring segment implantation, mechanical, femtosecond, keratoconus

(*Cornea* 2011;30:11–17)

The treatment of keratoconus has evolved considerably from the time it was first investigated in the late 19th century.[1] Although contact lenses or glasses might be prescribed for patients with milder forms of keratoconus, advanced keratoconus requires more invasive action. Contact lens intolerance in keratoconic eyes can pose problems with lens fitting, and for eyes in a more developed stage of keratoconus, surgery will most likely be the only viable option.

Penetrating keratoplasty and deep lamellar keratoplasty can be effective methods to treat advanced keratoconus, but the risks and complications that these procedures entail must be very carefully considered. In addition to a lengthy postoperative recovery period and the requirement of medication for several months after surgery, there are risks of the occurrence of vascularization of corneal tissue, substantial endothelial cell loss, and rejection of the graft.[2–6] Corneal transplantation can also require additional correction for anisometropia and astigmatism, which can require further invasive procedures such as laser in situ keratomileusis or the use of contacts lenses.[7,8] Rigid gas-permeable contact lenses can be effective in providing adequate visual results; however, this treatment entails practical and clinical problems because of the fitting of the lens over the irregular cone and may not be effective in eyes in a more advanced stage of keratoconus.[9–12]

From the surgeon's and the patient's perspective, treatment for keratoconus should entail minimal risk of complications, offer good visual results, a quick recovery, and minimal pain or discomfort. In the 1950s and 1960s, Barraquer[13] suggested the application of intrastromal implants for the correction of myopia and astigmatism. Over the years, this concept was investigated upon and developed, and it is now possible to implant intrastromal rings to treat ectasia.

Studies have already demonstrated that the implantation of intrastromal corneal ring segments allows for the safe and effective treatment of keratoconus, with good results up to 1 year after surgery, although being completely reversible.[14–17] Different types of intrastromal corneal rings were avaliable, depending on their curvature diameter and zone of implantation. The Keraring (Mediphacos, Belo Horizonte, Brazil) is an intrastromal corneal ring segment designed to correct surface irregularities and reduce refractive errors associated

with keratoconus and other ectatic corneal disorders. The Keraring flattens the central corneal curvature by providing the addition of tissue in the midperiphery, stabilizing the progression of ectasia. This study investigates the safety and efficacy of Keraring implantation for the treatment of various stages of keratoconus, using femtosecond-assisted tunnel creation and mechanical tunnel creation.

MATERIALS AND METHODS

In this study, 96 eyes of 75 patients with keratoconus were enrolled between August 2006 and December 2007. All patients had contact lens intolerance and clear central corneas. According to Amsler–Krumeich classification of keratoconus disease, 14 eyes (14.5%) were in stage I, 37 eyes (38.5%) were in stage II, 22 eyes (22.9%) were in stage III, and 23 eyes (23.9%) were in stage IV. Corneal tunnels were made using a femtosecond laser in 26 eyes and mechanically in 70 eyes. The Keraring (Mediphacos), with a 5-mm diameter and 160-degree arc length, was implanted in each eye according to the manufacturer's nomogram (Fig. 1).

Surgical Procedure

This study was approved by local ethical committees, and all patients gave informed consent of their involvement in the study. All surgical procedures were performed under topical anesthesia. For the first 70 eyes, the tunnel was created with mechanical spreader. For the remaining 26 eyes, the tunnel was created with femtosecond laser (Abbott Medical Optics, Inc, Santa Ana, CA), after it became available in our clinic.

Purkinje reflex was chosen as the central point and marked, and corneal thickness was measured using ultrasonic pachymetry at the 5-mm corneal diameter. Target localization of the intrastromal corneal ring was marked on the cornea and the stromal tunnel was created accordingly. Decentration was accepted if tunnel was created outside this area. After the ring location area was marked, a disposable suction ring (Moria, Inc, Doylestown, PA) was placed to minimize decentration. For manually created tunnels, a single entry incision was made on the steepest corneal topographic axis using a diamond blade. The tunnel depth was set at 70% of the thinnest corneal thickness. A counterclockwise and clockwise spatula was used for this method of manual tunnel creation. For femtosecond-assisted tunnel creation, single entry incision was 1 mm and made on the steepest corneal topographic axis using the 60 kHz IntraLase femtosecond laser (Abbott Medical Optics, Inc). The tunnel depth was set at 70% of the thinnest corneal thickness, and the inner diameter was set to 4.4 mm, whereas the outer diameter was set to 5.6 mm. The energy used for femtosecond-assisted tunnel creation and the entry incision was 1.30 μJ. The duration of the procedure with the femtosecond laser was approximately 15 seconds. The Keraring segments were implanted with special forceps after tunnel creation. In 77 eyes (80.2%), 2 segments were inserted, whereas in 19 eyes (19.8%), a single intrastromal ring segment was inserted.

In the first 31 eyes, during each surgery session, only one eye of each patient was implanted with the Keraring; if patients had ring segments implanted in both eyes, each eye was implanted during a different session. In the remaining 65 eyes, when the surgeon gained experience in Keraring implantation, bilateral surgery was performed. Postoperatively, antibiotic and steroid eyedrops were prescribed 4 times daily for 2 weeks.

S.E.	0/100	25/75	33/66	50/50
				
	All ectasia is limited to one half of the cornea.	75% of the ectasia in one half of the cornea and 25% situated in the other half.	Two thirds of the ectatic area in one half of the cornea and one third in the other half.	The ectasia is distributed evenly in both corneal halves.
>−10 D	25/35	25/35	30/35	35/35
−8 to −10 D	20/30	20/30	25/30	30/30
−6 to −8 D	15/25	15/25	20/25	25/25
−2 to −6 D	0/20	0/20	15/20	20/20
<−2 D	0/15	0/15	15/15	15/15

FIGURE 1. Manufacturer's normogram of segment distribution and thickness according to area of ectasia and SE.

Follow-up

A complete ophthalmic examination was performed preoperatively and postoperatively, including uncorrected visual acuity (UCVA), best spectacle–corrected visual acuity (BSCVA), spherical equivalent (SE), manifest spherical and cylindrical refraction, and keratometric readings using the Orbscan II (Bausch & Lomb, Rochester, NY). The follow-up period for all patients was at least 6 months and up to 18 months. Visual acuity was measured in Decimal Snellen and converted to logarithm of the minimum angle of resolution (logMAR) for statistical analysis.

Statistical Analyses

Statistical analyses were performed using the SPSS for Windows software (version 11.5; SPSS, Inc, Chicago, IL). Results are presented as mean ± SD and ranges. A 2-tailed probability of 5% or less was considered statistically significant.

RESULTS

The mean age of the patients was 26 ± 9 years (range, 18–44 years) with 35 men and 40 women. All 96 eyes have completed at least 6 months of follow-up, 69 eyes have completed 12 months of follow-up, and 54 eyes have completed 18 months of follow-up. All tunnel incisions and Keraring segment implantations were performed, without major intraoperative complications or decentration (Fig. 2).

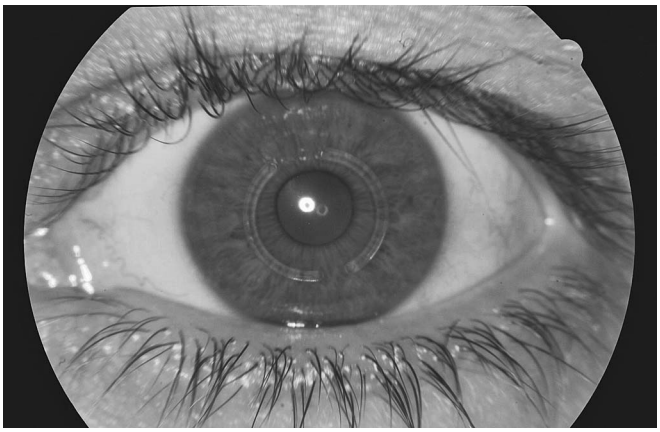

FIGURE 2. Successfully implanted Keraring segments displayed no signs of complications related to tunnel creation or segment implantation.

Visual Acuity

The mean preoperative UCVA for all eyes (n = 96) was 1.40 ± 0.39 logMAR (range, 0.3–1.60 logMAR). At the sixth postoperative month, the mean UCVA was 0.60 ± 0.34 logMAR (n = 96; range, 0–1.3 logMAR; $P < 0.001$), at the first year, the mean UCVA was 0.55 ± 0.33 logMAR (n = 69; range, 0–1.3 logMAR; $P < 0.001$), and at the 18th month, the mean UCVA was improved to 0.50 ± 0.32 logMAR (n = 54; range, 0–1.3 logMAR; $P < 0.001$). The mean preoperative BSCVA for all eyes (n = 96) was 0.68 ± 0.36 logMAR (range, 0.2–1.3). At the sixth month, the mean BSCVA was 0.29 ± 0.21 logMAR (n = 96; range, 0–1 logMAR; $P < 0.001$), at the 12th month, 0.28 ± 0.20 logMAR (n = 69; range, 0–1 logMAR; $P < 0.001$), and at the 18th month, it was improved to 0.26 ± 0.20 logMAR (n = 54; range, 0–1 logMAR; $P < 0.001$).

At the sixth month, UCVA improved in 87 eyes (90.6%), remained unchanged in 5 eyes (5.2%), and decreased in 4 eyes (4.1%) when compared with the preoperative levels. The mean difference between UCVA was a gain of 2.06 ± 1.81 Snellen lines [range loss of 2 lines to gain of 6 lines (Fig. 3)]. BSCVA improved in 87 eyes (90.6%), decreased in 4 eyes (4.1%), and remained unchanged in 5 eyes (5.2%) at the sixth month. The mean difference between BSCVA was a gain of 2.80 ± 2.17 lines [range loss of 3 lines to gain 9 lines (Fig. 4)]. Four eyes (4.1%) that were in stage IV keratoconus had decreased UCVA and BSCVA.

Refractive Results

The mean preoperative maximum keratometry (Kmax) for all eyes (n = 96) was 53.58 ± 5.90 diopters (D) (range, 43.70–65.40 D) and decreased to 49.02 ± 4.70 D (n = 96; range, 42.30–60.30 D; $P < 0.001$) at the sixth month, 49.14 ± 4.41 D (n = 69; range, 42.40–59.80 D; $P < 0.001$) at the 12th month, and 48.57 ± 4.36 D (n = 54; range, 42.40–59.60 D; $P < 0.001$) at the 18th month. Similarly, the mean preoperative keratometric astigmatism was 5.28 ± 2.64 D (n = 96; range, 0.90–13.70 D), which decreased to 2.71 ± 1.93 D (n = 96; range, 0.50–10.10 D; $P < 0.001$) at the sixth month, 2.71 ± 1.77 D (n = 69; range, 0.00–10.10 D; $P < 0.001$) at the 12th month, and 2.75 ± 1.84 D (n = 54; range, 0.50–10.00 D; $P < 0.001$) at the 18th month.

There was a statistically significant reduction in the SE refractive error from −5.88 ± 3.65 D (n = 96; range, −13.00 to −0.50 D) preoperatively to −2.14 ± 1.88 D (n = 96; range, −11.50 to 0.50 D; $P < 0.001$) at the sixth month, −2.14 ± 1.90 D (n = 69; range −10.50 to 0.00 D; $P < 0.001$) at the 12th month, and −2.26 ± 1.98 D (n = 54; range, −10.50 to 0.00 D; $P < 0.001$) at the 18th month. Figure 5 shows SE changes preoperatively to the sixth month, and Figures 6 and 7 show the respective preoperative and postoperative keratometric maps of a selected patient in this study, showing

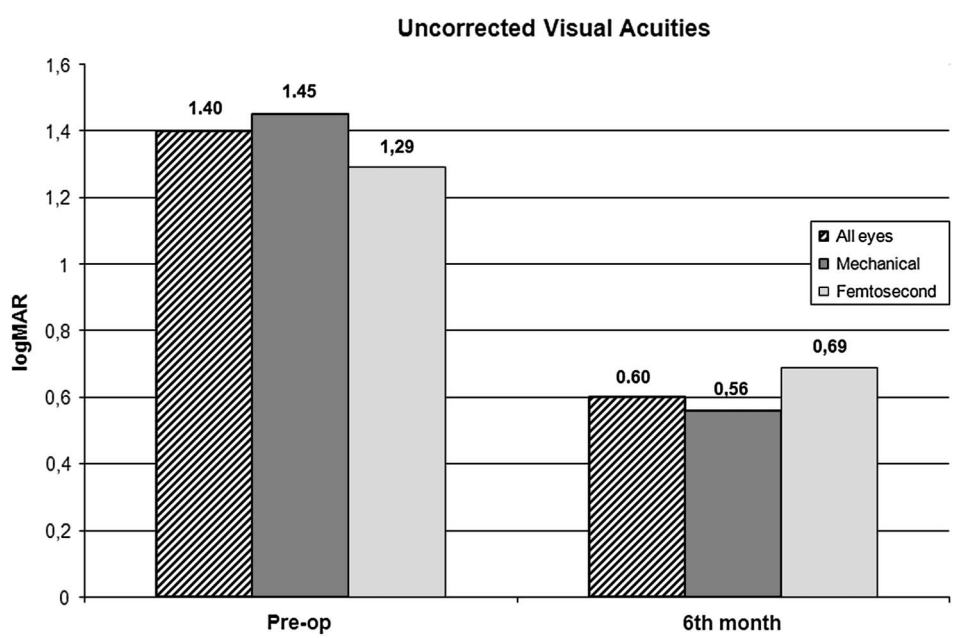

FIGURE 3. Bar graph demonstrating UCVA changes (logMAR) preoperatively and at the sixth month after Keraring implantation.

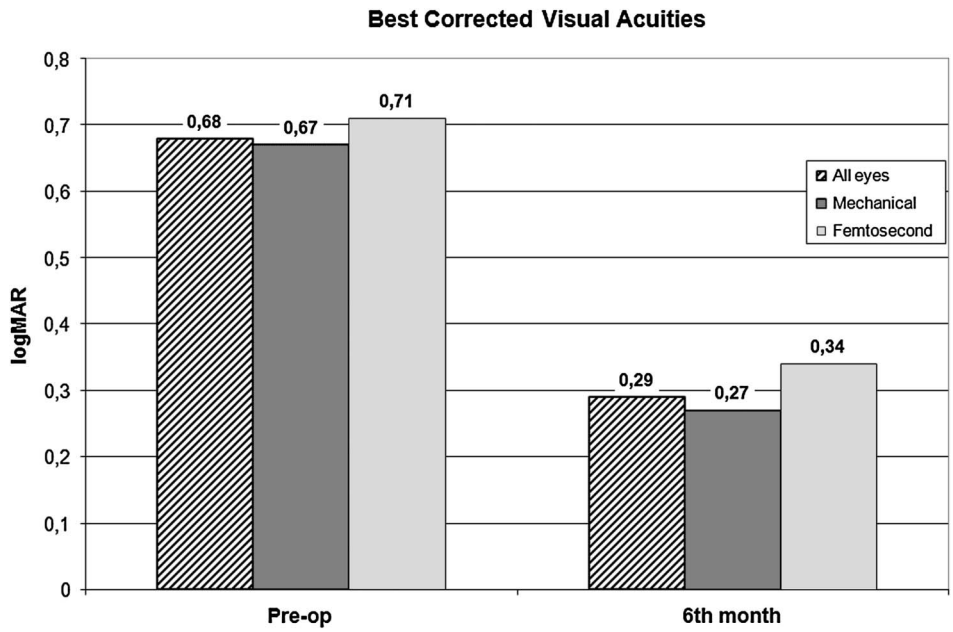

FIGURE 4. Bar graph demonstrating BSCVA changes (logMAR) preoperatively and at the sixth month after Keraring implantation.

a significant decrease in keratometric values 18 months after surgery.

When the outcomes of patients on whom we have data at each interval were analyzed, UCVA and BSCVA were found to be significantly improved after 18 months (n = 54, Table 1). Also, outcomes such as SE refractive error, maximum keratometry, and keratometric astigmatism were significantly decreased after 18 months in the same group (n = 54, Table 1).

Mechanical Versus Femtosecond Laser Tunnel Creation

A summary of the results for each group, including mean age and mean change for each parameter, is shown in Table 2. According to Amsler–Krumeich classification, there was no statistically significant difference between both groups regarding keratoconus stages (P = 0.66, χ^2 test). Preoperatively to the 6th month, there was no statistically significant difference between both groups in mean change in any parameter (Table 2).

Complications and Observations

In the mechanical group, 21 eyes (30%) had limited epithelial defects at the site of incision on the first postoperative day, which resolved sponteneously in a few days. Superficial Keraring segment placement was seen in 1 eye, and the intrastromal corneal tunnel was recreated at the appropriate

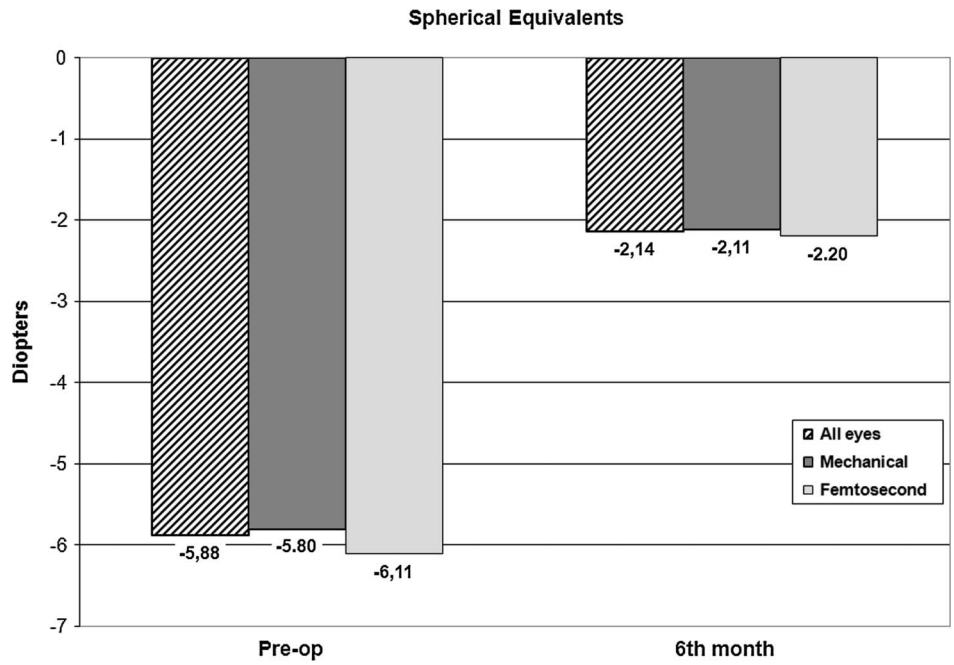

FIGURE 5. Bar graph demonstrating SE changes preoperatively and at the sixth month after Keraring implantation.

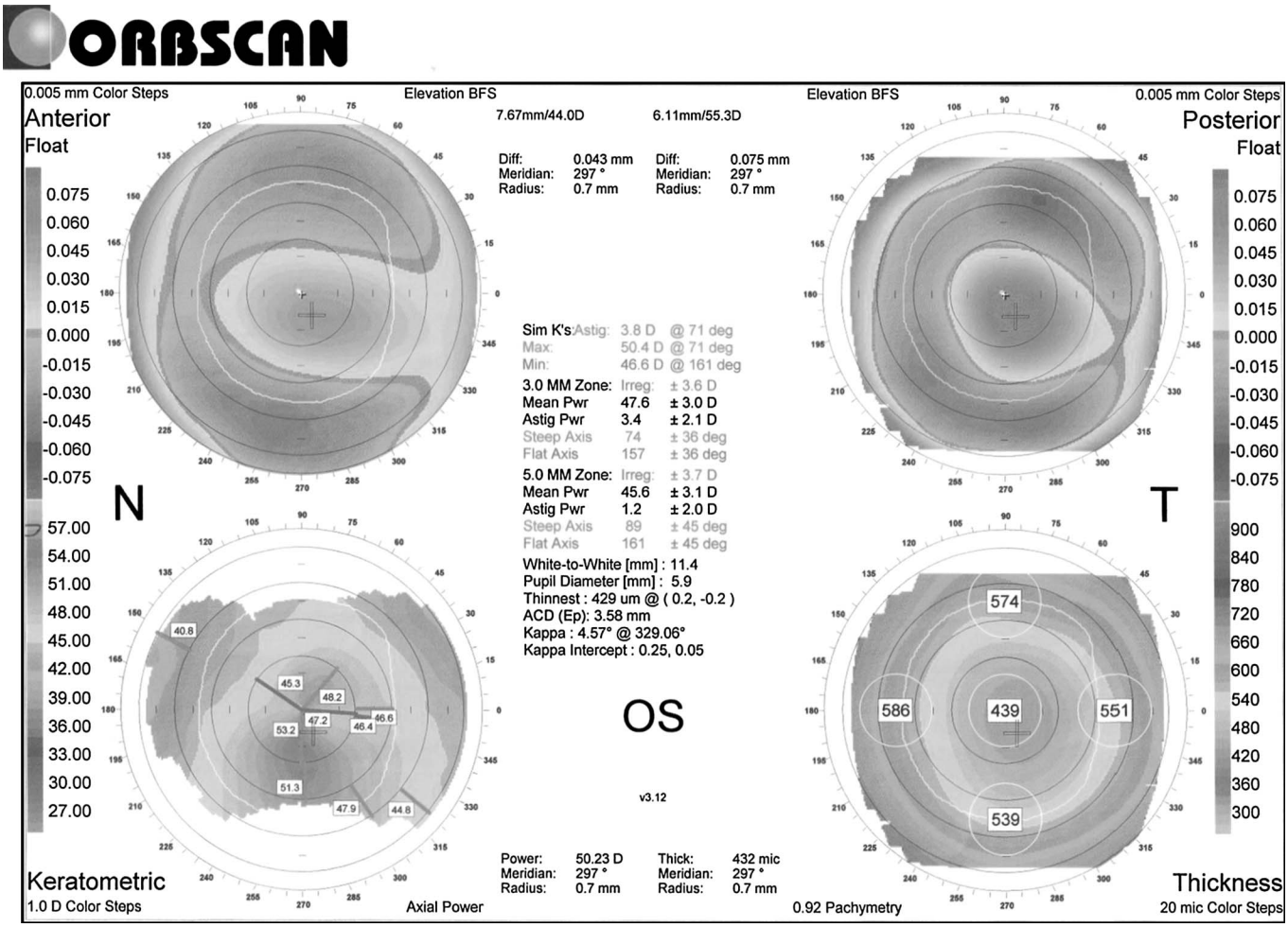

FIGURE 6. Preoperative keratometric map of a selected patient, showing a relatively high amount of astigmatism.

depth and the segments were reimplanted into the new corneal tunnel at the first week after the first operation.

In the femtosecond group, at the first postoperative month, segment migration to the incision site was seen in 1 eye. The migrated segment was repositioned away from the incision site, and the segment stayed stable thereafter.

White deposits were observed in the segment tunnels of 56 eyes (58.3%). Two patients were not satisfied with their vision and requested corneal transplantation.

DISCUSSION

In this study, the implantation of the Keraring resulted in the safe and effective therapeutic treatment of keratoconus in all eyes. There was a significant improvement in visual acuity results, with a larger improvement in UCVA compared with BSCVA, and significant improvements in refractive results, echoing results reported in previous studies.[16,18]

Recently, Shabayek and Alió[16] published a case series of patients with keratoconus followed up for 6 months after Keraring implantation using a femtosecond laser. They reported a mean UCVA increase from 0.06 to 0.3 (decimal scale) and BSCVA increase from 0.54 to 0.71. In this study, these visual results were 1.40–0.60 logMAR and 0.68–0.29 logMAR, respectively, after 6 months. Coskunseven et al[18] reported 1-year results of patients with keratoconus who underwent Keraring implantation. The mean difference between preoperative and postoperative UCVA was a gain of 1.7 lines and BSCVA was a gain of 1.3 lines. In our results, there was a UCVA gain of 2.06 lines and BSCVA gain of 2.80 lines after 6 months.

In the current study, visual and refractive changes were compared between mechanical intracorneal tunnel–created eyes (n = 70) and femtosecond tunnel–created eyes (n = 26). Although visual and refractive results of mechanical group seem to be better than femtosecond group, there was no statistically significant difference between 2 groups at the sixth month after surgery. Recently, Rabinowitz et al[19] compared the sixth month results of femtosecond group and the 12th month results of mechanical group in Intacs implanted keratoconus eyes retrospectively. Contradictory to our results, in their study, femtosecond group had better outcomes; however, there was no statistically significant difference between 2 groups as in our study. Further prospective randomized studies are needed to have a definitive opinion about this subject.

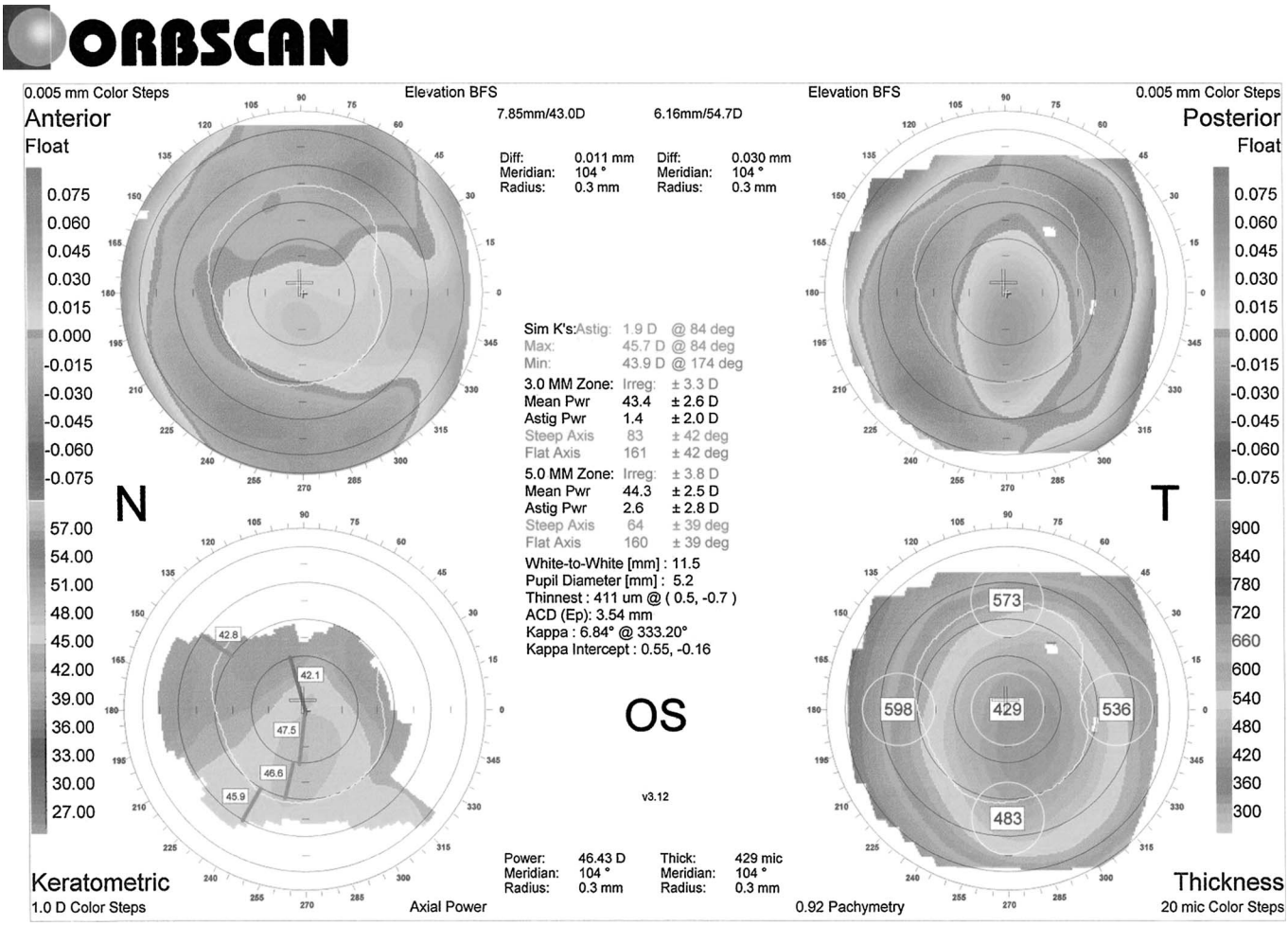

FIGURE 7. Keratometric map of the same patient 18 months postoperatively, showing a significant improvement in the amount of astigmatism.

Complications were reported for intrastromal corneal ring segment implantation by mechanical spreaders, including epithelial defects, anterior or posterior corneal perforation with spreaders, superficial placement of the rings, segment movement, infectious keratitis from introduction of epithelial cells into the tunnel, and corneal stromal edema around the channel.[20,21] In the present study, more complications were observed in the mechanical group compared with the femtosecond group. Rabinowitz et al[19] reported a 50% rate of postoperative significant epithelial defects with the mechanical tunnel dissection method. In the present study, in the mechanical group, 30% of the eyes had epithelial defects at the site of incision and superficial Keraring segment placement was seen in 1 eye. Coskunseven et al[18] reported the segment migration to the incision site in 6% of the eyes at the first postoperative day with the femtosecond-assisted tunnel creation method. Similarly, segment migration to the incision site was observed in 3.8% of the eyes in the femtosecond group in our study.

TABLE 1. Visual, Refractive, and Keratometric Outcomes in Patients Who Completed Each Follow-up Visit

	Preoperative	Sixth Mo	First Yr	18th Mo	*P** (Preoperatively to the 18th Mo)
Eyes (n)	54	54	54	54	—
UCVA (logMAR)	1.42 ± 0.37	0.51 ± 0.33	0.52 ± 0.21	0.50 ± 0.32	<0.001
BSCVA (logMAR)	0.62 ± 0.30	0.25 ± 0.20	0.25 ± 0.13	0.26 ± 0.20	<0.001
SE (D)	−6.10 ± 3.31	−2.19 ± 2.11	−2.27 ± 1.98	−2.26 ± 1.98	<0.001
Kmax (D)	52.78 ± 5.84	48.61 ± 4.56	48.82 ± 4.44	48.57 ± 4.36	<0.001
Kast (D)	5.19 ± 2.80	2.76 ± 1.84	2.72 ± 1.85	2.75 ± 1.84	<0.001

Values are given in mean ± SD.
*Wilcoxon signed rank test.
Kast, keratometric astigmatism.

TABLE 2. Comparison of Data (Change in Parameter) Between Mechanical and Femtosecond Group After 6 Months

	Mechanical Group (n = 70)	Femtosecond Group (n = 26)	*P**
Age (yrs)	25.67 ± 8.90	28.08 ± 8.44	—
UCVA† (lines)	2.08 ± 1.73	1.50 ± 2.31	0.18
BSCVA† (lines)	2.93 ± 2.04	2.19 ± 2.76	0.15
SE† (D)	3.78 ± 3.16	3.75 ± 4.33	0.93
Spher† (D)	3.02 ± 3.02	3.03 ± 4.72	0.90
Cylinder† (D)	1.64 ± 2.17	1.63 ± 1.93	0.99
Kmax† (D)	4.66 ± 2.94	4.62 ± 2.93	0.89

Values are given in mean ± SD.

*Paired *t* test was used for data with normal distribution; Wilcoxon test was used for data without distribution.

†Change in parameter.

Cylinder, manifest cylindrical refraction; Kast, keratometric astigmatism; Spher, manifest spherical refraction.

The prevalence of white deposits in the segment tunnel was common (56 eyes). Deposits have been reported to occur frequently after the implantation of intrastromal corneal rings,[22,23] and Ruckhofer et al[20] have noted that the occurrence and density of the deposits increased with the thickness of the segment and the duration of implantation. The study also observed that the presence of deposits in the tunnels did not affect the optical performance of the intrastromal corneal rings or the anatomical or physiological structure of the cornea. The incidence of adverse optical effects may be reduced with the Keraring because the ring is designed to reduce the incidence of glare and halos through a prismatic effect that reflects refracted light out of the eye. However, studies have reported a higher prevalence of complications such as inflammation or infection in mechanical tunnel creation, although these were not observed in our study.[15,19,24–26]

In conclusion, intrastromal corneal ring segments like the Keraring offer safe and effective therapeutic treatment for patients with keratoconus who are not suited to other procedures. While contact lenses are not always effective, especially for patients with advanced keratoconus, the surgical options, such as penetrating keratoplasty and deep lamellar keratoplasty, are more invasive and entail a moderate amount of risk of complication or rejection. Keraring implantation is a viable alternative, providing safety and good visual outcomes after both mechanical and femtosecond-assisted tunnel creation.

REFERENCES

1. Pearson RM. Kalt, keratoconus, and the contact lens. *Optom Vis Sci*. 1989; 66:643–646.
2. Ohguro N, Matsuda M, Shimomura Y, et al. Effects of penetrating keratoplasty rejection on the endothelium of the donor cornea and the recipient peripheral cornea. *Am J Ophthalmol*. 2000;129:468–471.
3. Watson SL, Tuft SJ, Dart JK. Patterns of rejection after deep lamellar keratoplasty. *Ophthalmology.* 2006;113:556–560.
4. Amayem AF, Anwar M. Fluid lamellar keratoplasty in keratoconus. *Ophthalmology.* 2000;107:76–79; discussion 80.
5. Patel N, Mearza A, Rostron CK, et al. Corneal ectasia following deep lamellar keratoplasty. *Br J Ophthalmol*. 2003;87:799–800.
6. Olson RJ, Pingree M, Ridges R, et al. Penetrating keratoplasty for keratoconus: a long-term review of results and complications. *J Cataract Refract Surg*. 2000;26:987–991.
7. Perl T, Charlton KH, Binder PS. Disparate diameter grafting. Astigmatism, intraocular pressure, and visual acuity. *Ophthalmology.* 1981;88: 774–781.
8. Weed KH, McGhee CN. Referral patterns, treatment management and visual outcome in keratoconus. *Eye*. 1998;12:663–668.
9. Zhou AJ, Kitamura K, Weissman BA. Contact lens care in keratoconus. *Cont Lens Anterior Eye*. 2003;26:171–174.
10. Lema I, Durán JA, Ruiz C, et al. Inflammatory response to contact lenses in patients with keratoconus compared with myopic subjects. *Cornea*. 2008;27:758–763.
11. Dana MR, Putz JL, Viana MA, et al. Contact lens failure in keratoconus management. *Ophthalmology.* 1992;99:1187–1192.
12. Lembach RG. Use of contact lenses for management of keratoconus. *Ophthalmol Clin North Am*. 2003;16:383–394.
13. Barraquer JI. Modification of refraction by means of intracorneal inclusions. *Int Ophthalmol Clin*. 1966;6:53–78.
14. Siganos CS, Kymionis GD, Kartakis N, et al. Management of keratoconus with Intacs. *Am J Ophthalmol*. 2003;135:64–70.
15. Kwitko S, Severo NS. Ferrara intracorneal ring segments for keratoconus. *J Cataract Refract Surg*. 2004;30:812–820.
16. Shabayek MH, Alió JL. Intrastromal corneal ring segment implantation by femtosecond laser for keratoconus correction. *Ophthalmology.* 2007;114: 1643–1652.
17. Miranda D, Sartori M, Francesconi C, et al. Ferrara intrastromal corneal ring segments for severe keratoconus. *J Refract Surg*. 2003;19:645–653.
18. Coskunseven E, Kymionis GD, Tsiklis NS, et al. One-year results of intrastromal corneal ring segment implantation (KeraRing) using femtosecond laser in patients with keratoconus. *Am J Ophthalmol*. 2008;145:775–779.
19. Rabinowitz YS, Li X, Ignacio TS, et al. INTACS inserts using the femtosecond laser compared to the mechanical spreader in the treatment of keratoconus. *J Refract Surg*. 2006;22:764–771.
20. Ruckhofer J, Twa MD, Schanzlin DJ. Clinical characteristics of lamellar channel deposits after implantation of intacs. *J Cataract Refract Surg*. 2000;26:1473–1479.
21. Kanellopoulos AJ, Pe LH, Perry HD, et al. Modified intracorneal ring segment implantations (INTACS) for the management of moderate to advanced keratoconus: efficacy and complications. *Cornea*. 2006;25:29–33.
22. Alió JL, Artola A, Hassanein A, et al. One or 2 Intacs segments for the correction of keratoconus. *J Cataract Refract Surg*. 2005;31:943–953.
23. Colin J. European clinical evaluation: use of INTACS for the treatment of keratoconus. *J Cataract Refract Surg*. 2006;32:747–755.
24. Alió JL, Shabayek MH. Complications of Intrastromal corneal ring segments. In: Alió JL, Azar DT, eds. *Management of Complications in Refractive Surgery.* New York, NY: Springer; 2008:297–306.
25. Carrasquillo K, Rand J, Talamo JH. Intacs for keratoconus and post-LASIK ectasia. Mechanical versus femtosecond laser–assisted channel creation. *Cornea*. 2007;26:956–962.
26. Shehadeh-Masha'our R, Modi N, Barbara A, et al. Keratitis after implantation of intrastromal corneal ring segments. *J Cataract Refract Surg*. 2004;30:1802–1804.

